

Inflammation of Organs in Autistic Children

Research Article

Shui Yin Lo*

Director of Quantum Health Research Institute Pasadena, USA

Received: Aug 28, 2020; **Accepted:** Sept 07, 2020; **Published:** Sept 08, 2020

***Corresponding author:** Shui Yin Lo, Director of Quantum Health Research Institute Pasadena, CA 91107, USA

Copyright: © 2020 Shui Yin Lo. This is an open-access article distributed under the terms of the Creative Commons Attribution License, which permits unrestricted use, distribution, and reproduction in any medium, provided the original author and source are credited.

Abstract

Following the previous paper “Diagnosis, prevention, and treatment of Autism via Meridian theory” 2012, we continue our work on three aspects of inflammation of organs in autistic children. The first aspect is to study the organs with inflammation of an autistic child with great detail. We did that for three cases. The second aspect it to study the variety of inflammation of the same organ, say the inflammation of the eye of different subjects. Each inflammation is different in shape and severity. The third aspect was that for 28 cases we found.

(i) 100% autistic children had inflammation of thyroid. (ii) More than 61% autistic children had overactive immune system. (iii) More than 50% autistic children had problems with their large intestine. (iv) More than 21.4% autistic children had problem with their small intestine. (v) More than 46.4% autistic children had problems with their reproductive organs. We conclude that it is important to continue in future that study of many more cases confirms this finding of inflammation of organs in autistic children.

Keywords: Autism; Inflammation; Organs; Solid water particles; Brain; Thyroid; Immune system; Large intestine; Small intestine; Reproductive organs

Introduction

According to the official DSMV, Autistic Spectrum Disorder (ASD) is defined as a neurodevelopmental behavior disorder (American Psychiatric Association, 1994) and is considered to be a brain dysfunction. The ASD problem was getting more serious year by year. From the statistics published by Center for Disease Control Center the ratio of autistic children to normal children increased from 1/150 in year 2000 to 1/58 now. There are three approaches to study ASD.

The first approach is to use Western Medicine. The causes of ASD are both genetic and environmental. The environmental causes were obvious there, but it was difficult to find, and impossible to quantify. As genes are much easier to measure, there are many more studies [1-

10]. The studies showed that the gene origin of ASD was quite complex [2]. The second approach is to use tradition Chinese medicine to treat ASD [11-17]. They are mainly acupuncture and qigong massage.

The third approach is to use two high tech products that come from synthesizing Chinese medicine with quantum physics [18-23]. They were developed gradually in the last twenty years. The first product is solid water particles (SWP, earlier it was called stable-water-clusters), which is composed of pure water molecules that are aligned with positive charge on one end, and negative charge on the other end. Solid water particles are the constituents of meridians. Diseases are considered to come from blockage of meridians. When meridians are unblocked,

qi (energy) and blood will flow smoothly. When organs obtained sufficient nutrients from blood, organs will repair themselves, recover their own self-healing power, and become healthy again. Traditional acupuncture can unblock the meridian by inserting needles at the right acupoints.

Now drinking liquid with SWP can act like acupuncture, unblock meridians, let qi-blood flow smooth again, enable organs to recover self-healing mechanism, and become healthy again. Whereas for acupuncture to work, it is necessary to know which meridian, and which acupoint to put the needles, drinking solution with SWP, SWP will go automatically to the right place to unblock meridians. But how do you know drinking solution with SWP will help autistic children? A new infrared image device is used. The new device is the second-high tech invention. With a special designed software and enough experience, it is possible to tell which organ is inflamed from the body surface temperature. The degree of inflammation is measured numerically by the temperature of the body surface. The higher the body surface temperature, the more serious inflamed is the organ. In a previous case study of ASD result was presented that there was a success rate 72.7% of improvement in autistic children. Improvement is judged objectively and numerically from the decrease of inflammation of organs in autistic children.

More than one hundred cases have since been seen, and treated. The success rate remained approximately 70%. Twenty-five cases with infrared images were collected into one book: "Autism and Stable Water Clusters" [23].

In the following we study the inflammation of organs in autistic children. Besides the inflammation of the brain, there are at least five organs that are inflamed: thyroid, lymph node under the armpit, large intestine, small intestine, and reproductive organs. In section 2 the inflammation of various organs in three cases were discussed in detail. In Section 3 inflammation of the same organs in different cases were shown. They were different in shape and color. The spectrum of Autism Disorder (ASD) was probably a reflection of differences in inflammation of various organs.

Detailed study of inflammations of organs in three cases

An inflamed organ emits infrared radially to all direction. Most of the infrared is absorbed by the muscle and tissues around it. The rest of the infrared is transmitted

by connective tissue, and meridian line passes through it [18]. If the connective tissue above the inflamed organ is perpendicular to the body surface, inflamed organs will be seen above it. Meridians act like optical fibers and transmit infrared to the places where meridians are close to the surface. An inflamed brain cannot be seen in most place in the head, because skull and hair surrounds most surface of the brain except the forehead, the eyes, and the middle of the ear at acupoints SJ2. An inflamed thyroid cannot be seen at the frontal part of the neck because infrared emitted from thyroid cannot penetrate the muscle and tissue of the neck. Only Stomach meridian, which act like an optical fiber, carry the infrared from an inflamed thyroid to acupoints ST12, near the collar bone, then we see inflamed thyroids as two white dots at ST12. The left and right side of thyroid are shown as horizontal part of Small Intestine at the bottom part of the left and right side of the neck.

An inflamed small intestine is not seen in the abdominal area, but Small Intestine meridians carry the infrared from the inflamed small intestine to the left and right side of the neck. An inflamed Small Intestine meridian shows up as a white straight line on the side of the neck. An inflamed horizontal large intestine could be seen above the abdominal area.

The color code of the infrared images is: white (3 °C higher than normal skin temperature) the hottest, then red (2 °C higher than normal), yellow (1 °C higher than normal) and green, which represents the normal skin temperature.

Case 1: two-and-a-half-year boy:

The grandma brought her two-and-a-half-year boy to our study. Since birth, he required suppositories to excrete. He showed little interest in food, seemed addicted to milk and was in the 25th percentile of height and weight in comparison with other children his age. He had problems sleeping, exhibited excessive crying. His attention was only on his mother, and paid no attention to his grandma whom he lived with. He also had a fear of swings, slides and body rides. We immediately took infrared images of the two-and-a-half-year boy. The infrared images were shown in (Figure 1) below. Then he drank some solid water particles. Cream with solid water particles was applied to his abdominal area for one and half month.

1. Inflammation of the eyes. Inflammation of the eyes, which was shown in white color, indicated that the part of brain behind his eyes has problem. The processing power of brain behind the eyes was too weak. Hence, he preferred

to look at only his mother. He had little power left over to look at his grandma, or anyone else.

The inflammation of the eye region was shown in (Figure 1.1a).

The inflammation of the eyes was greatly reduced after one and half month (Figure 1.1b).

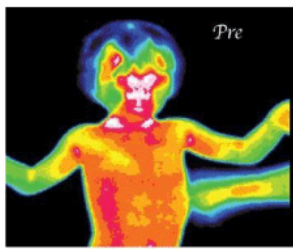


Figure 1: 1a

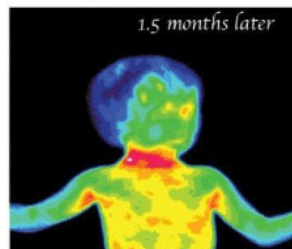


Figure 1: 1b.

Two large white dots of the eyes became a pale red dot with yellow region around them. He started to pay attention to his grandma.

2. Inflammation of the brain: The inflammation of right forehead shown as a white dot was an indication that the right frontal lobe of the brain did not function properly

3. Inflammation of the thyroid. Below the front neck there were two white dots, which were acupoints of stomach meridian ST 12. The left and right white dots indicated both the left and right thyroid were inflamed, and did not function properly. A boy with abnormal thyroid had low metabolism and little energy to play swings, slides as other normal energetic boys wanted to do.

4. Inflammation of large intestine. The inflammation of the large intestine showed up above the abdominal part as shown in (Figure 1.2a).

When large intestine did not function properly, he had constipation. After one-and-a-half-month treatment, the

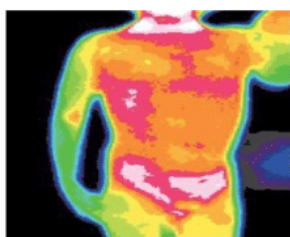


Figure 1: 2a

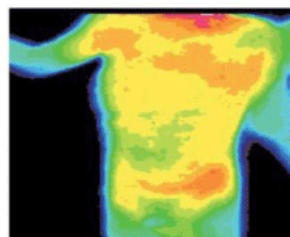


Figure 1: 2b.

white large intestine area reduced temperature to become red area, as shown in (Figure 1.2b). He did not require suppositories to excrete any more.

5. The inflamed left thyroid was shown as white thick line of Small Intestine as shown in (Figure 1.3a). Thick white line was reduced in area by about 50% after one and half month treatment as shown in (Figure 1.3b).

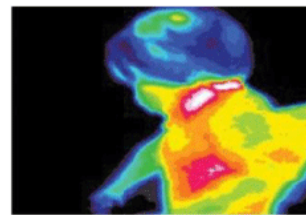

Figure 1: 3a

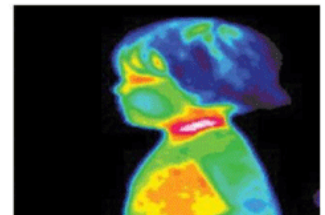

Figure 1: 3b.

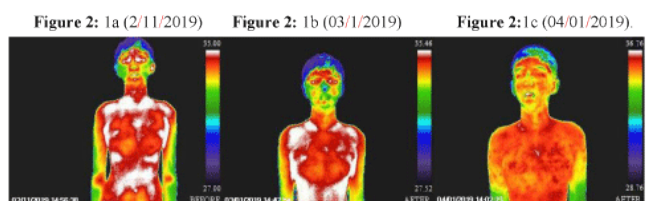
Case 2: 13-year autistic boy:

He came to visit us first time on 2/1/2019, then second time on 3/1/2019, and the third time 04/01/2019. He drank two bottles of Xen water™ (60ml) daily in this two month period. Each bottle had at least 3 million solid water particles. We took one set of whole body infrared pictures each time he came. They were shown below in (Figure 2).

Let us go through the features of these infrared pictures of different part of the body of this autistic boy to see the improvement in these two months:

1. The front pictures of upper body (Figure 2.1a, 1b, 1c).

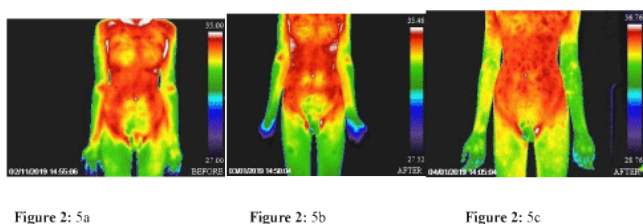
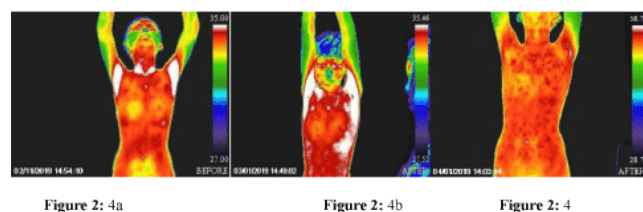
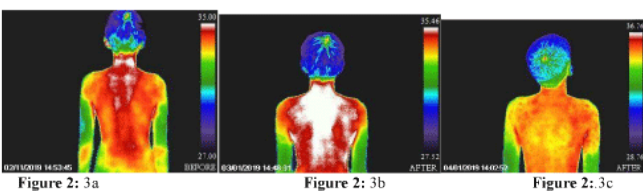
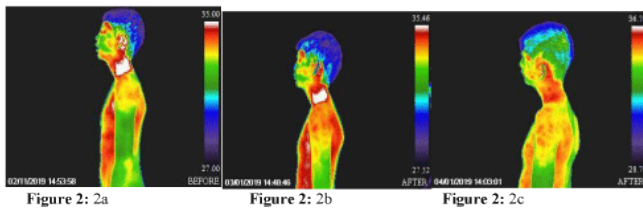
The inflammation of white dot on the center of the forehead, which reflected the inflammation in the frontal lobe of the brain, decreased to red color. It meant that the temperature of inflammation of frontal Lobe decreased by 1 °C. The change of color from white to red indicated the numerical degree of Improvement of the frontal Lobe. There were at least ten thousand pixels in each infrared picture. Each pixel had a numerical temperature accurate to 0.07 °C. So, the decrease of inflammation could be measured much better if it was necessary. The inflammation of the eyes was reduced from large white dots to two small white dots, and



then to red. The improvement of the frontal lobe behind the eyes was obvious, and could be numerical measured if it became necessary. The inflammation of the thyroid shown as white color area below the neck was reduced to large white dot, and then to red color. It indicated thyroid was becoming more and more functional, and the boy became more energetic.

The inflammation of the lung could be inferred from the inflammation of the left and right shoulder top of the acupoints LU2 of the lung meridian. The large white color changes to smaller area and then to red in two months' time. When the lung recovered its function, there will be more oxygen in the blood. The boy will have more energy to perform a variety of task.

The inflammation in the center of breast (acupoint RN 17) was shown in a large white dot, and then became a small white dot, and almost disappear after two months of treatment with solid water particles. Our experience with other cases indicated inflammation at RN15 meant too much stomach acid.



2. The Left Side (Figure 2. 2a, 2b, 2c).

Inflammation at the neck (Small Intestine meridian) was shown as large white area, and then disappeared into red area in two months' time. When small intestine is inflammation, the absorption of nutrient would be decreased. Therefore, the boy was thin, and underweight. With the recovery of the small intestine, he should gradually increase weight.

3. The back (Figure 2. 3a, 3b, 3c).

Inflammation of the two-vertical white line (Bladder meridians) on the upper back indicated the function of bladder was not normal. Then two months later the two white lines disappeared into red background. The bladder became normal.

4. The armpits (Figure 2. 4. a, b, c).

The inflammation was two large white color area at the armpit (acupoint HT 1), which indicated an overactive immune system. The white area disappeared into red indicated the immune system became normal again.

5. The toxin (Figure 2. 5a, b, c).

Toxins: The whole frontal area was slightly inflamed in red color. Then two months later red dots appeared. Our experience showed that red dots indicated toxins. Where did the toxins come from? The diet of the boy was quite carefully prepared. The boy breathed normal air. The toxin could come from his mother. When the mother gave birth to the baby, the mother got rid of her toxin by dumping into the baby. Now the boy recovered and started to secrete toxins. Toxins on the skin generally caused uncomfortable feeling. The easily irritated boy might be due the toxins.

Case 3: 18-year autistic girl:

She came to our office first on 4/3/2019, took a complete set of infrared pictures, which was shown in (Figure 3), below, and drank two bottles of Xen water™ daily for two weeks. Then another set of infrared pictures was taken on 4/16/2019. (Figure 3.1 a, b).

Inflammation of the forehead, which showed the inflammation of the frontal lobe, reduced from deep red to red indicated small improvement of the frontal lobe. Inflammation of the eyes expressed as red ring around the eyes stayed as red color. So that part of the brain that processing images seemed to stay the same. Inflammation of thyroid was expressed as two white dots in the two side of the front neck, (acupoint ST 12). It indicated her

metabolism was slow, and growth was retarded. She was much shorter than normal, and underweight.

After two weeks treatment, the right white dot disappeared and the size of white dot on the left reduced by half. This indicated that she had improvement in metabolism (Figure 3. 2a, b).

Inflammation of the right thyroid which was indicated by a large white area at the side of right neck, was reduced more than 90% to a small white dot. The metabolism of the right thyroid improved greatly in two weeks (Figure 3. 3a, b).




Figure 3: 1a

Figure 3: 1b

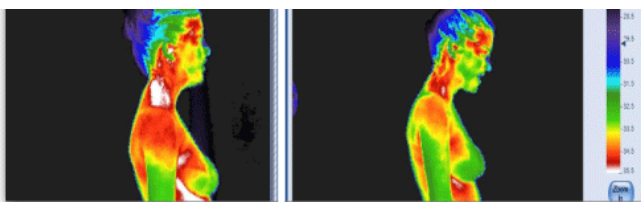


Figure 3: 2a

Figure 3: 2b

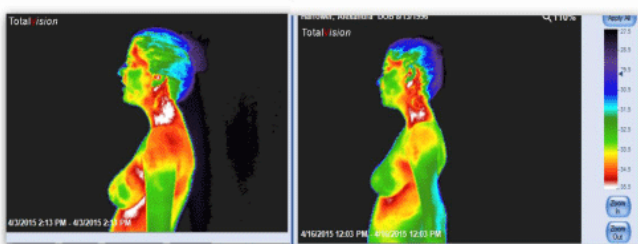


Figure 3: 3a

Figure 3: 3b

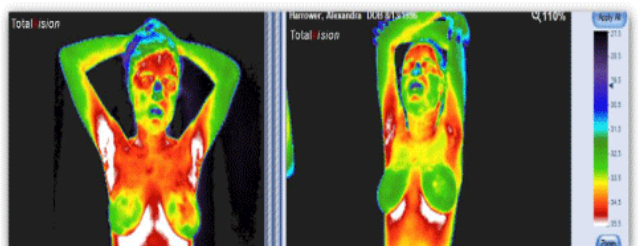


Figure 3: 4a

Figure 3: 4b

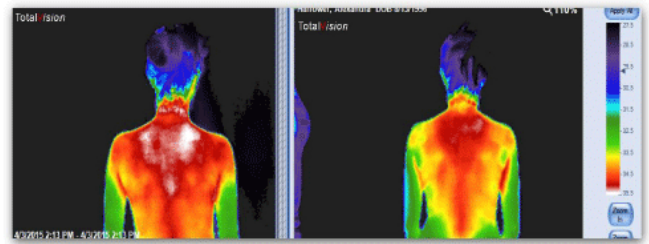


Figure 3: 5a

Figure 3: 5b

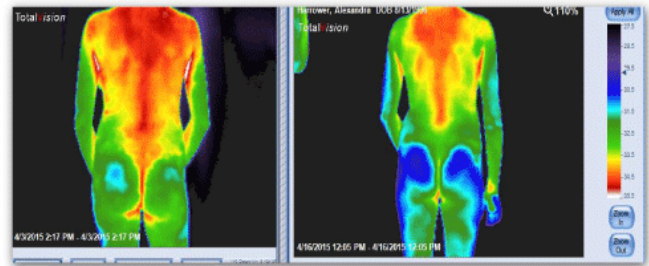


Figure 3: 6a

Figure 3: 6b

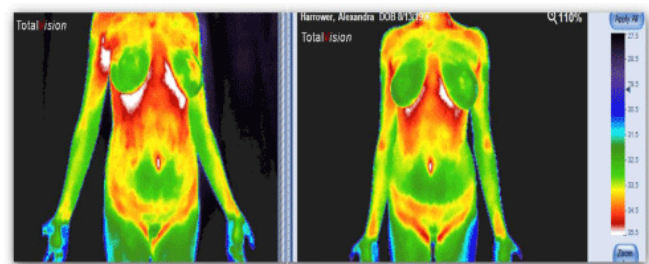


Figure 3: 7a

Figure 3: 7b

Inflammation of the left thyroid, which was indicated by a large white area on the left neck, was reduced by 80% area to two large white dots. The metabolism of the left thyroid improved greatly in two weeks (Figure 3. 4a, b). Inflammation of the lymphatic nodes at the armpit (the position of Heart Meridian acupoint HT1) was shown as the large white area, indicating an overactive immune system. The large white area was more than 95% reduced after two weeks of drinking Xen water™. Her immune system became almost normal again.

(Figure 3. 5a, b) the inflammation of Bladder meridian as shown two white area at the upper back was reduced into red color.

(Figure 3. 6 a, b) the inflammation of the DU meridian at the lower back was red in color. Some part of the red was gone by two weeks' time.

(Figure 3. 7 a, b). The inflammation of both the left and right breast was indicated by two white area, which was greatly reduced after two weeks.

Inflammation of various organs, three cases each

The inflamed organs were: eyes, forehead, left and right side of the head, thyroid, Lymph node, large intestine, small intestine, Bladder and reproductive organs. The cases were selected from 25 subjects S1, S2, to S25 studied over the years. The inflammations of the brain and thyroid of these 25 subjects plus the three cases above are listed in (Table 1). The inflammation of Lymph, large intestine, Small intestine, and reproductive organs are listed in

(Table 2). From Table 1, % = cases with inflammation of thyroid/cases with inflammation of the brain =100%. There was 100% correlation between the inflammation of the brain and the inflammation of the thyroid. From Table 2: % = cases with inflammation of the lymph node under the armpit/cases with inflammation of the brain = 61%

% = cases with inflammation of the large Intestine/ cases with inflammation of the brain = 50%

% = cases with inflammation of the small intestine/ cases with inflammation of the brain = 21.4%

Table 1: Inflammation *of brain, and thyroid of ASD children

Gender	Age	Eyes	Brain Forehead frontal lobe left side head right side head	SJ21, GB14	SJ21, GB14	Thyroid ST12	SI	Additional**
m	2.5	L, R	L, R			L, R	L	nose, BL
m	13	L, R	M			L, R		lung LU2
f	18	L, R	L, M, R		SJ21, GB14		L, R	DU-spine
m	6	L, R	L, R		GB14	L, R		
m	4	L, R	R			L, R		
m	10	L, R	L, R	SJ21, GB14		L, R		right LU2
m	3	L, R	L, M, R			L, R		
m	4	L, R	L, R			L, R		
m	4	L, R				L, R		
m	4	L, R	L			L, R		
m	5	L, R				R		
m	7	L, R				L, R		
m	3	L, R				R		
m	12	L, R		SJ21		#		nose
f	12	L, R				L	L	
m	12	R			SJ21		R	
m	24	L, R		SJ21	SJ21	L, R		
m	5	R				L, R	L	BL
m	15	L, R				L		
m	7	L, R			SJ21, GB14	L, R		
m	3	L, R				L, R		
m	21	L, R			Sj21	L, R		SJ behind ear
m	15	L, R		SJ21, GB14		#		toxin
m	12	L, R	horizontal		SJ21	L, R		SJ behind ear
m	9	L, R	L, R	SJ21, GB14		R		
m	9	L, R	L, R		GB14	L, R		
m	10	L, R	L, R		SJ21	R		
m	7	L, R			SJ21, GB14	L, R		SJ behind ear

%= cases with inflammation of the organ/cases with inflammation of the brain 100% for inflammation of thyroid

*We do not make distinction of the degree of inflammation **Younger autistic children did not like being photography. So inflammation of many parts of body was not recorded.

Table 2: Inflammation of lymph, large intestine, small intestine, and reproductive organs.

ASD	gender	Age	Lymph armpit HT1 Immune sys	Large intestine LI abdominal	small intestine SI	Reproductive organs RN1
1	m	2.5		horizontal		
2	m	13	L,R	L,R	neck	
3	f	18	L,R			L, R breast
S1	m	6	#	horizontal		RN1
S2	m	4	L,R			
S3	m	10		L, R	L, R	RN1
S4	m	3	L, R	horizontal		
S5	m	4	L, R	L, R		RN1
S6	m	4	L, R	L, R		RN1
S7	m	4	L, R			
S8	m	5	L, R	horizontal		
S9	m	7	L, R	horizontal, L, R		
S10	m	3	L, R			
S11	m	12	L, R			
S12	f	12				
S13	m	12	L			RN1
S14	m	24		L, R	L, R	RN1
S15	m	5	L		L	
S16	m	15	R			RN1
S17	m	7		horizontal		RN1
S18	m	3		L		
S19	m	21			L, R neck	
S20	m	15	L, R	L, R		RN1
S21	m	12	L, R	horizontal		RB1
S22	m	9	L, R			
S23	m	9			R neck,	RN1
S24	m	10				
S25	m	7				

%= cases with inflammation/cases with inflammation of the brain 61% , 50% , 21.4% 46.4% for the lymph ,the Large Intestine, Small intestine, and reproductive organ asd child did not raise hands, 1, S3, S12, S17, S18, S19, S23, 24, 25.

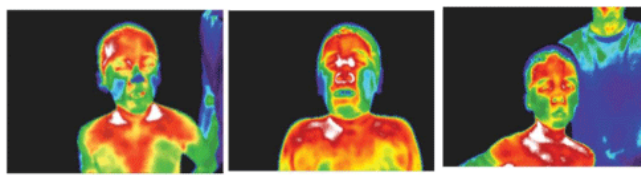
%= cases with inflammation of reproductive organs/
cases with inflammation of the brain = 46.4%

a. Inflammation of eyes:

S1, S8, S9 Left,

middle and right Infrared images above were from S1, S8, and S9 There was nothing wrong with the eyes. The

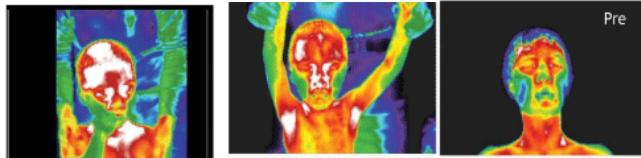
inflammation of eyes indicated inflammation of the frontal lobe behind the eyes. Differences in the shapes indicated the position and function of the inflamed frontal lobe were different for three cases. The difference in color, white being of higher temperature (3 °C higher than normal), indicated the function of that part frontal lobe was more severely affected.



S1

S8

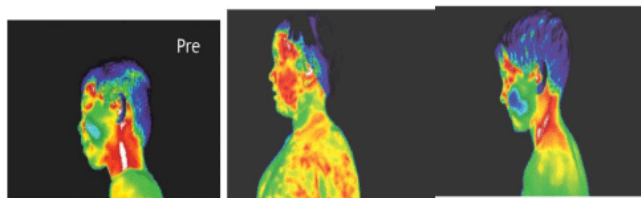
S9



S3

S4

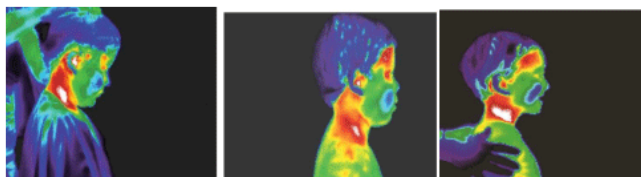
S5



S3

S20

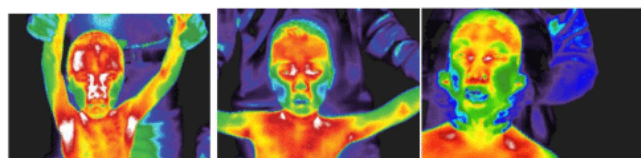S22



S13

S17

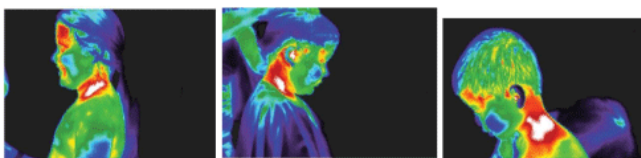
S25



S4

S5

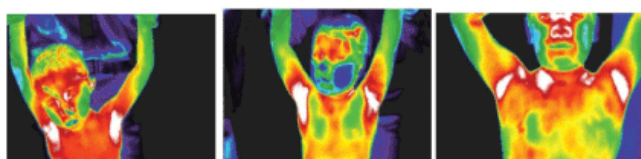
S11



S12

S13

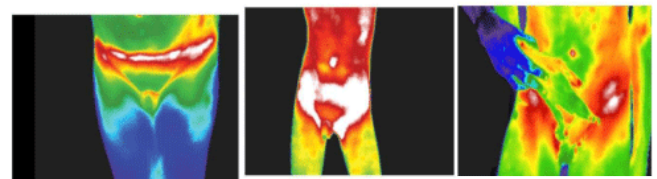
S15



S5

S7

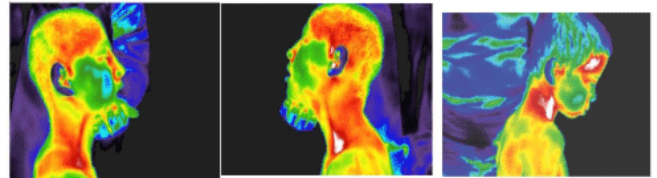
S8



S8

S9

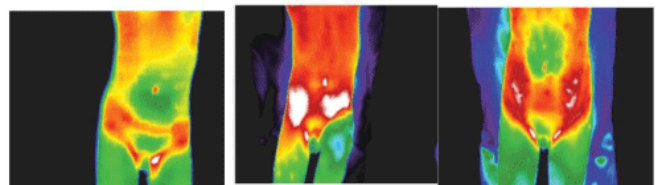
S1



S14R

S14L

S23



S1

S5

S6

b. Inflammation of the forehead: S3, S4, S5

S3, S4, S5

The inflammation of the frontal lobe on case S3 was more severe than that of case 4, and the inflammation of the frontal lobe of case S4 was more severe than that of case S5

c. Inflammation of the left side head: S3, S20, S22

S3, S20, S22

The inflammations of the left temporal lobe were different for these three cases.

d. Inflammation of the right side of the head: S13, S17, S25

S13, S17, S25

The inflammation of right temporal lobe of case S13 was more severe than that of S17, and the inflammation of temporal lobe of S17 was more severe than that of S25

e. Inflammation of thyroid-front: S4, S5, S11

S4, S5, S11

The inflammation of the thyroid-front of S5 was more severe than that of S4, and the inflammation of the thyroid-front of S4 was more severe than that of S11

f. Inflammation of thyroid-side: S12, S13, S15

S12, S13, S15

The inflammation of the thyroid-side of S15 was more severe than that of S13, and the inflammation of thyroid-side of S13 was more severe than that of S12

g. Inflammation of lymph node at the armpit. S5, S7, S8

S5, S7, S8

The inflammations of the lymph node under the armpits were different for these three cases

h. Inflammation of Large intestine: S8, S9, S1

S8, S9, S1

The inflammation of large intestine of S9 was more severe than that of S8, and the inflammation of large intestine of S8 was more severe than that of S1.

i. Inflammation of Small intestine-neck: S14R, S14L, S23

S14R, S14L, S23

The inflammation of small intestine of S23 was more severe than that of S14L, and the inflammation of small intestine of S14L was more severe than that of S14R.

j. Inflammation or reproductive organs: S1, S5, S6

S1, S5, S6

The inflammations of the prostrate (RN1) of these three cases were different.

Conclusion

The results of our 28-case study here on the inflammation of organs in autistic children showed that: 1) spectrum of Autism Disorder (ASD) was a reflection a spectrum of degree of inflammation of various organs. 2) 100% autistic children had problems with their thyroid. 3) More than 61% autistic children had overactive immune system. 4) More than 50% autistic children had problem with their large intestine. 5) More than 21.4% autistic children had problems with their small intestine. 6) More than 46.4% autistic children had problems with their reproductive organs.

It is important to study many more cases to determine the correlation between inflammation of the brain and the inflammation of other organs of the autistic children. Then we can conclude that autistic children have problems of their organs besides their brain.

References

1. Ivanov HY, Stoyanova VK, Popov NT and Vachev TI, Autism Spectrum Disorder - A Complex Genetic Disorder, *Folia Med (Plovdiv)*. 2015; 57: 19-28.
2. Hua R, Wei MP and Zhang C. The complex genetics in autism spectrum disorders, *Sci China Life Sci*. 2015; 58: 933-945.
3. Sharma SR, Gonda X and Tarazi FI, Autism Spectrum Disorder: Classification, diagnosis and therapy *Pharmacol Ther*. 2018; 190: 91-104.
4. Accordino RE, Kidd C, Politte LC, Henry CA and McDougle CJ. Psychopharmacological interventions in autism spectrum disorder *Expert Opin Pharmacother*. 2016; 17: 937-952.
5. Marchezan J, Dos Santos EGAW, Deckmann I and Dos Santos Riesgo R. Immunological Dysfunction in utism Spectrum Disorder: A Potential Target for Therapy, *Neuroimmunomodulation*. 2018; 25: 300-319.
6. Bengner M, Kinali M and Mazarakis ND. Autism spectrum disorder: prospects for treatment using gene therapy *Mol Autism*. 2018; 9: 39.
7. Sathe N, Andrews JC, McPheeters ML and Warren ZE. Nutritional and Dietary Interventions for Autism Spectrum Disorder: A Systematic Review. 2017; 139: e20170346.
8. Randell E, McNamara R, Delpont S, Busse M, Hastings RP and Gillespie D, et al. Sensory integration therapy versus usual care for sensory processing difficulties in autism spectrum disorder in children: study protocol for a pragmatic randomized controlled trial. 2019; 20: 113.
9. Sakulchit T, Ladish C and Goldman RD. Hyperbaric oxygen therapy for children with autism spectrum disorder, *Can Fam Physician*. 2017; 63: 446-448.
10. Mangiola F, Ianiro G, Franceschi F, Fagioli S, Gasbarrini G and Gasbarrini A. Gut microbiota in autism and mood disorders, *World J Gastroenterol*. 2016; 7;22: 361-368.
11. Yau CH, Ip CL and Chau YY. The therapeutic effect of scalp acupuncture on natal autism and regressive autism. 2018; 13: 30.
12. Lee B, Lee J, Cheon JH, Sung HK, Cho SH and Chang GT. The efficacy and Safety of Acupuncture for the Treatment of Children with Autism Spectrum Disorder: A Systematic Review and Meta-analysis. *Evid Based Complement Alternat Med*. 2018; 11: 1057539.
13. Abo Almaali HMM, Gelewkhana A and Mahdi ZAA, Analysis of Evidence-Based Autism Symptoms Enhancement by Acupuncture, *Acupuncture Meridian Stud*. 2017; 10: 375-384.
14. Ayres R., Budden S, Bunse C, Shalock M and Silva LMT. Qigong massage treatment for sensory and self-regulation problems in young children with autism: a randomized controlled trail. *Am. J. Occup. Ther*. 2009; 63: 423-432.
15. Chan AS, Cheung MC and Sze SL. Seven-star needle stimulation improves language and social interaction of children with autistic spectrum disorders *Am J Chin Med*. 2009; 37: 495-504.
16. Hui KK, Jui J, Kwong KK, Marina O and Rosen BR. Acupuncture, the limbic system, and the auto correlated networks of the brain. *Auton. Neurosci*. 2010; 157: 81-90.
17. Jia, SW, Sun TT and Fan R. Visualized study on acupuncture treatment of children autism using single photon emission computed tomography. *Zhongguo Zhong Xi Yi Jie He Za Zhi*. 2008; 28: 886-889.
18. Lun F, Huangsheng C, Deheng C, Shixun Y, Jianrong X and Eryu C, Experimental exploration and research prospect of physical bases and functional characteristics of meridians, *Science Bulletin*. 1998; 43: 1233-1251.

19. Shui YL. Meridians in acupuncture and infrared imaging. Med. Hypothesis. 2002; 58: 72–76.
20. Lo SY. Biophysics Basis for Acupuncture and Health. Dragon Press, Pleasantville, 2004.
21. Lo SY, Geng X and Gann D. Evidence for the existence of stable-water-clusters at room temperature and normal pressure. Physics Lett. 2009; 373: 3872–3876.
22. Lo SY, Diagnosis, Treatment and Prevention of Autism via Meridian Theory, The American Journal of Chinese Medicine. 2012; 40: 39-56.
23. Lo SY. Autism and Stable Water Clusters, Quantum Health Research Institute, 2013.
24. Lo SY. Acupuncture & Infrared Imaging, EHG Books. 2018.